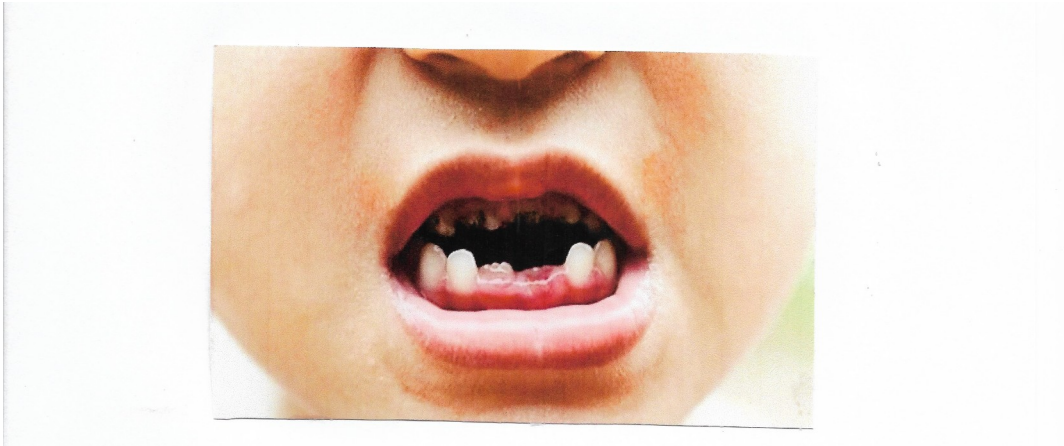
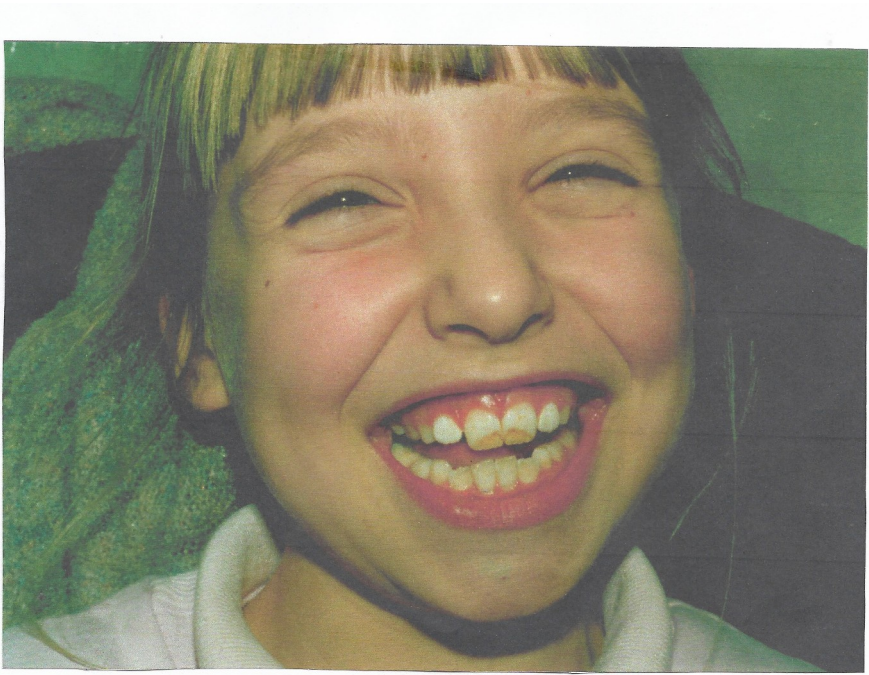

Appendix 2

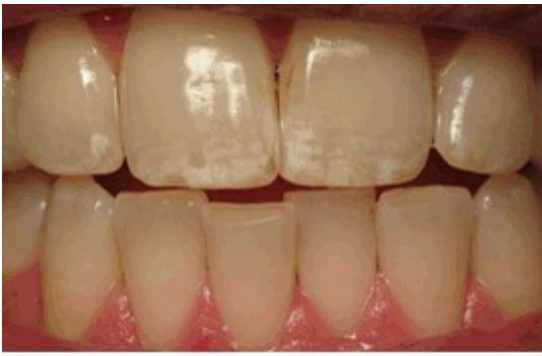a) Baby bottle tooth decay



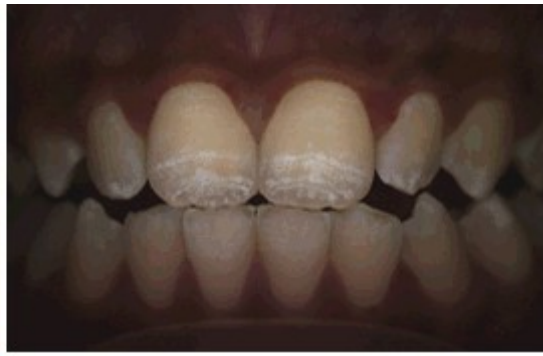b) Dental fluorosis



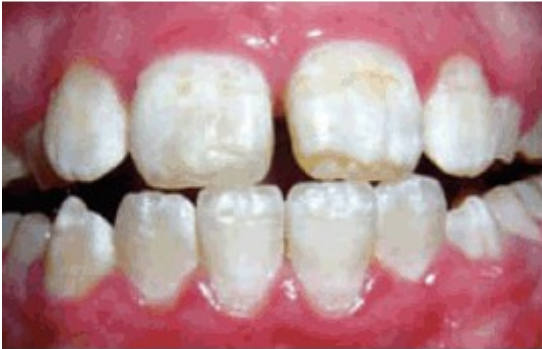Lisa



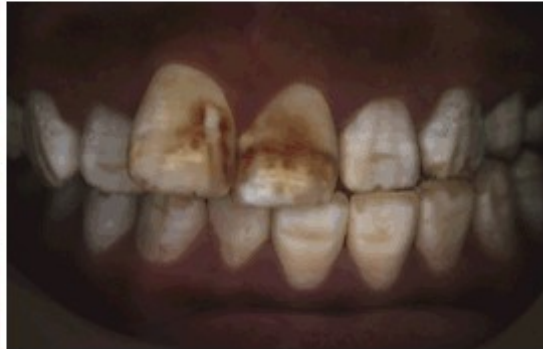“Very Mild”



“Mild”



“Moderate”

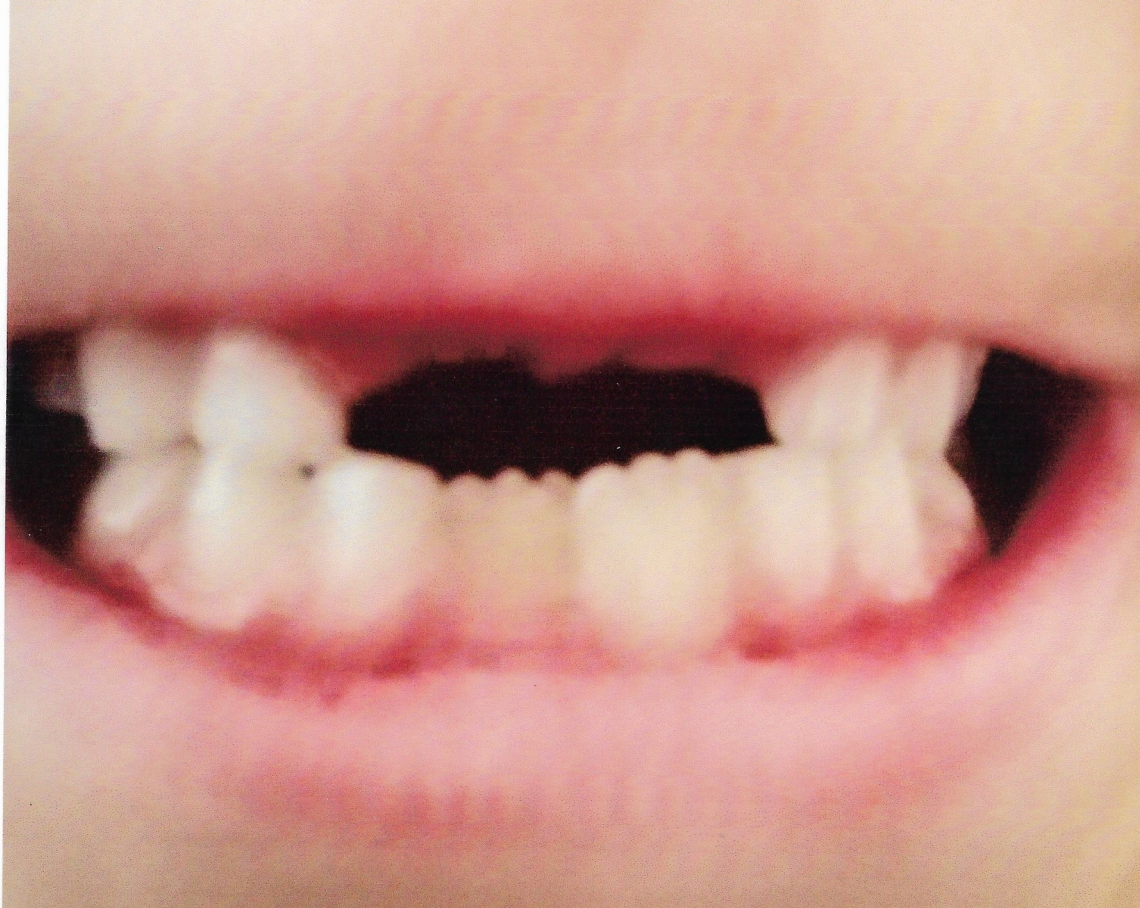

“Severe”

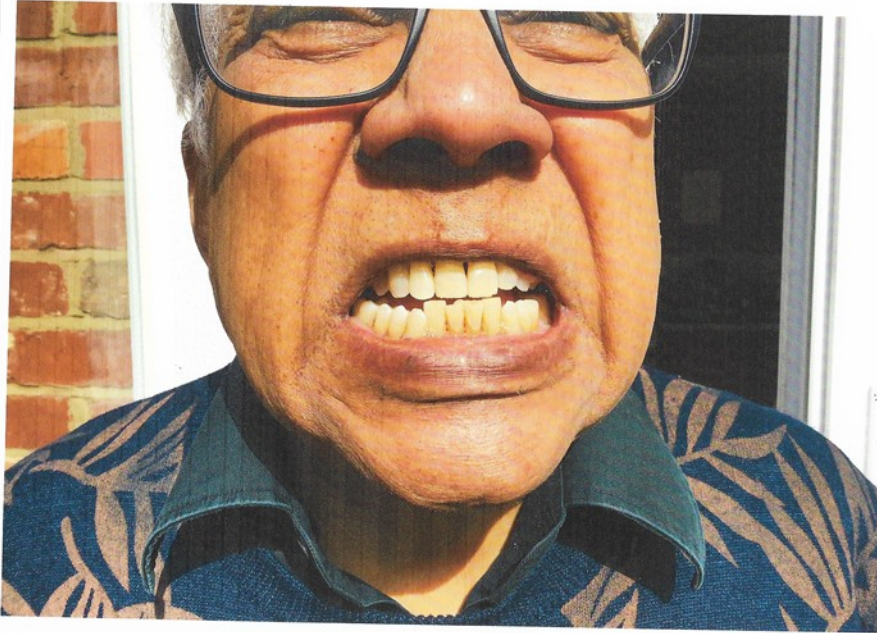
Degrees of Dental Fluorosis

Sourced from FAN's website – www.fluoridealet.org

C) Hypomineralisation. A boy of seven years-old.



d) Perfect teeth. A gentleman of 82 years with all his own beautiful teeth. He has never had a filling and only in recent years lost three perfect back teeth due to abscesses. As a child he always swilled his mouth with water after eating. Toothpaste was used very occasionally and then only by rubbing a little across the teeth with a finger. He was born, and grew up, in India, Calcutta before coming to live in England in his early twenties.



Friday 16th April 2021

e) Four pictures of crippling skeletal fluorosis and one picture of a bony, calcified, outgrowth from Nalgonda and Nasipur in India, 1997, where well water contained high calcium fluoride levels.

(Source – People For Poisoned Children - PFPC)

